

A human brain network derived from coma-causing brainstem lesions

David B. Fischer, MD*
Aaron D. Boes, MD,
PhD*
Athena Demertzi, PhD
Henry C. Evrard, PhD
Steven Laureys, PhD
Brian L. Edlow, MD
Hesheng Liu, PhD
Clifford B. Saper, MD,
PhD
Alvaro Pascual-Leone,
MD, PhD
Michael D. Fox, MD,
PhD‡
Joel C. Geerling, MD,
PhD‡

Correspondence to
Dr. Fischer:
d.b.fisch@gmail.com
or Dr. Fox:
foxmdphd@gmail.com

Supplemental data
at Neurology.org

ABSTRACT

Objective: To characterize a brainstem location specific to coma-causing lesions, and its functional connectivity network.

Methods: We compared 12 coma-causing brainstem lesions to 24 control brainstem lesions using voxel-based lesion-symptom mapping in a case-control design to identify a site significantly associated with coma. We next used resting-state functional connectivity from a healthy cohort to identify a network of regions functionally connected to this brainstem site. We further investigated the cortical regions of this network by comparing their spatial topography to that of known networks and by evaluating their functional connectivity in patients with disorders of consciousness.

Results: A small region in the rostral dorsolateral pontine tegmentum was significantly associated with coma-causing lesions. In healthy adults, this brainstem site was functionally connected to the ventral anterior insula (AI) and pregenual anterior cingulate cortex (pACC). These cortical areas aligned poorly with previously defined resting-state networks, better matching the distribution of von Economo neurons. Finally, connectivity between the AI and pACC was disrupted in patients with disorders of consciousness, and to a greater degree than other brain networks.

Conclusions: Injury to a small region in the pontine tegmentum is significantly associated with coma. This brainstem site is functionally connected to 2 cortical regions, the AI and pACC, which become disconnected in disorders of consciousness. This network of brain regions may have a role in the maintenance of human consciousness. *Neurology*® 2016;87:2427-2434

GLOSSARY

AI = anterior insula; **ARAS** = ascending reticular activating system; **MCS** = minimally conscious state; **pACC** = pregenual anterior cingulate cortex; **rs-fcMRI** = resting-state functional connectivity MRI; **VEN** = von Economo neuron; **VS/UWS** = vegetative state/unresponsive wakefulness syndrome.

Arousal, or wakefulness, is an integral component of consciousness and prerequisite for other brain functions, yet its neuroanatomy in humans is poorly understood. Classically, the brainstem “reticular formation” has been considered important for wakefulness.¹ Experiments in rodents suggest this brainstem area can be subdivided into functionally discrete regions, and that injury to one region in the pontine tegmentum reliably disrupts arousal and produces coma.² A homologous brainstem region is likely present in humans, based on analysis of coma-causing lesions.³ However, it remains unclear whether there is a human brainstem site significantly more associated with coma-causing lesions than with non-coma-causing lesions, and exactly where this site is located. Such a brainstem site would likely maintain

*These authors contributed equally to this work.

‡These authors contributed equally to this work.

From the Berenson-Allen Center for Noninvasive Brain Stimulation, Division of Cognitive Neurology, Department of Neurology (D.B.F., A.D.B., A.P.-L., M.D.F.), and Department of Neurology (C.B.S., A.P.-L., M.D.F., J.C.G.), Harvard Medical School and Beth Israel Deaconess Medical Center, Boston; Harvard Medical School (D.B.F.), Boston; Departments of Pediatric Neurology (A.D.B.) and Neurology (B.L.E.), Harvard Medical School and Massachusetts General Hospital, Boston, MA; Brain and Spine Institute (Institut du Cerveau et de la Moelle épinière-ICM) (A.D.), Hôpital Pitié-Salpêtrière, Paris, France; Coma Science Group (A.D., S.L.), GIGA-Research & Cyclotron Research Centre, University and University Hospital of Liège, Belgium; Functional and Comparative Neuroanatomy Lab (H.C.E.), Centre for Integrative Neuroscience, Tübingen; Max Planck Institute for Biological Cybernetics (H.C.E.), Tübingen, Germany; Athinoula A. Martinos Center for Biomedical Imaging (B.L.E., H. L., M.D.F.), Massachusetts General Hospital, Charlestown, MA.

Go to Neurology.org for full disclosures. Funding information and disclosures deemed relevant by the authors, if any, are provided at the end of the article.

arousal through ascending projections to other brain regions (originally termed the ascending reticular activating system, or ARAS),^{1,4} but this network of brain regions in humans is also unclear.

Here, we aim to identify the brainstem region affected by coma-causing lesions and its functional connectivity network. First, we localize coma-causing brainstem lesions, using strict clinical criteria for coma, and statistically compare these to control lesions that do not impair conscious wakefulness. Second, we use connectome data derived from resting-state functional connectivity MRI (rs-fcMRI) to determine the network associated with these brainstem lesions in healthy individuals. Finally, we investigate the functional connectivity of this network in patients with disorders of consciousness.

METHODS See appendix e-1 at Neurology.org for a full description of the methods. In a case-control design, we first collected a series of focal brainstem lesions—which either caused coma or were “controls” (i.e., did not impair conscious wakefulness)—from local cases and cases reported in the literature. Lesions were delineated by CT, MRI, or autopsy (see table e-1). We reproduced all lesions onto a template brain, separately overlapped coma and control lesions, and compared locations of the 2 lesion groups through 2 methods: subtracting the control from the coma lesions, and conducting voxel-based lesion-symptom mapping (computing the degree to which each voxel is preferentially involved by coma lesions as compared to control lesions).⁵ These methods identified a “coma-specific region” of the brainstem significantly more affected by coma-causing lesions compared to control lesions.

We then used rs-fcMRI to investigate the brain network associated with our coma-specific brainstem region.^{6,7} Rs-fcMRI identifies spatially disparate regions of the brain that exhibit synchronous (i.e., correlated) fluctuations in the fMRI signal. To identify this region’s connectivity network in the normal brain, we utilized a normative rs-fcMRI dataset acquired from 98 right-handed, healthy participants (48 men, ages 22 ± 3.2 years).⁷ By measuring fluctuations in activity in the coma-specific region, and correlating those fluctuations to those of all other voxels in the brain, we identified regions “functionally connected” to the coma-specific brainstem region (t value > 4.25, indicating regions of correlation at $p < 0.00005$, uncorrected). We also used a voxel-wise t test to determine whether these identified regions were significantly more connected to coma lesions than to control lesions.

At the standard rs-fcMRI statistical threshold of $t > 4.25$, our primary analysis identified only cortical connectivity, and failed to identify functional connectivity to subcortical sites previously implicated in arousal.^{2,4,8,9} We therefore relaxed statistical thresholds and examined connectivity specifically to some of these structures, such as the thalamus ($t > 3.75$, $p < 0.0005$, uncorrected), hypothalamus, basal forebrain, amygdala, and bed nucleus of the stria terminalis ($t > 2$, $p < 0.05$, uncorrected).

Each subcortical structure was tested for connectivity to coma lesions vs control lesions.

We compared the topography of the cortical regions identified by our network analysis to that of previously defined resting-state networks.^{10,11} Although correspondence to such networks was poor, we noted that these cortical regions resembled the previously reported locations of von Economo neurons (VENs) (see discussion). To assess the correspondence between the identified network nodes and the distribution of VENs in the human brain, we used MRI and histology of a postmortem brain to develop a brain-wide mask of VEN distribution. We then quantitatively evaluated the correspondence of the identified cortical nodes to the brain-wide VEN distribution, as well as to previously defined resting-state networks.^{10,11} For each node, we expressed overlap as: (voxels within both node and mask)/(voxels within node).

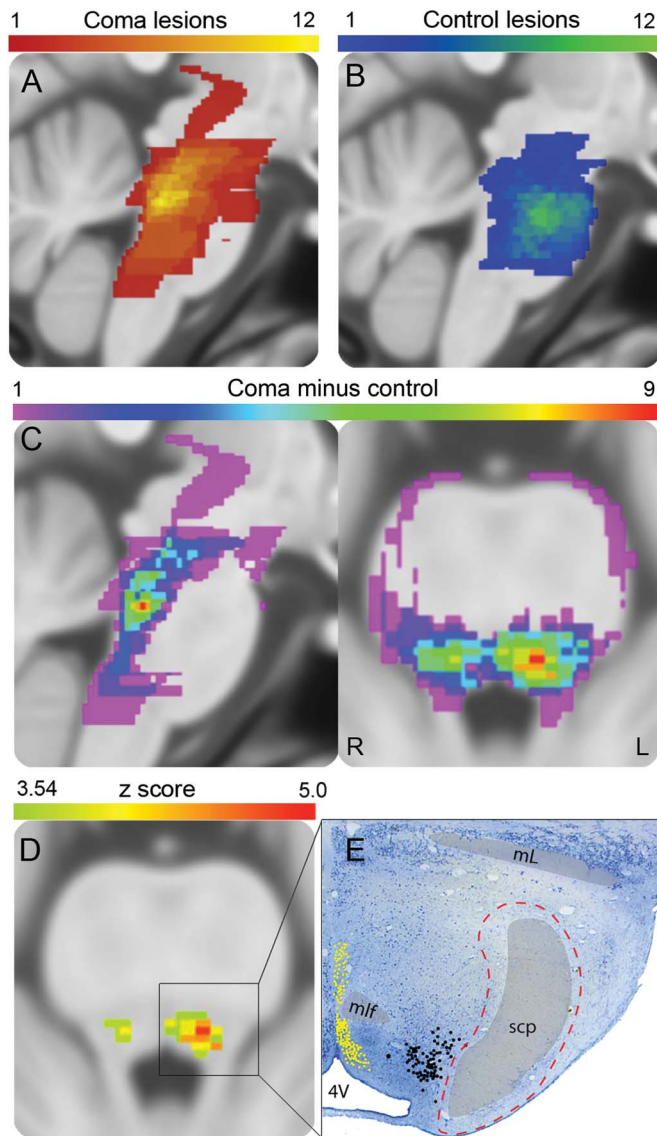
To assess connectivity of the identified network in disorders of consciousness, we used an independent rs-fcMRI dataset acquired from 26 patients in a minimally conscious state (MCS), 19 patients in a vegetative state/unresponsive wakefulness syndrome (VS/UWS), 6 patients in coma, and 21 age-matched healthy controls. We compared connectivity between the 2 cortical nodes of our network to connectivity between nodes of the default mode network and motor network. We then compared network connectivity between healthy controls, patients with coma, and patients with disorders of consciousness characterized by impaired awareness (MCS and VS/UWS). We collapsed across MCS and VS/UWS in our main analysis to maximize statistical power and because connectivity between our cortical nodes did not significantly differ between these conditions. To standardize across networks, we expressed internode connectivity as a ratio of connectivity in healthy controls. We used t tests to identify whether network connectivity differed from zero, differed between groups, or differed between networks.

Standard protocol approvals, registrations, and patient consents. The Partners Institutional Review Board approved this study. See appendix e-1 for a full description of lesion collection and patient recruitment.

RESULTS Lesion analysis. We collected 36 focal brainstem lesions from patients encountered locally or described in the literature.^{3,12–15} Twelve lesions caused coma (7 local cases, 5 literature cases; mean age 57.3 ± 16.5 years; mean lesion volume 3,540 ± 2,988 mm³) while 24 control lesions did not (8 local cases, 16 literature cases; mean age 58.1 ± 12.8 years; mean lesion volume 2,364 ± 2,644 mm³). There was no significant difference in lesion volume between the coma and control cases ($p = 0.26$). See table e-1 and figure e-1A for additional case details.

Coma-causing lesions maximally overlapped in the pontine tegmentum (10 of 12 cases; figure 1A). In contrast, control lesions primarily involved the pontine base (11 of 24; figure 1B). Subtracting control lesions from the coma lesions, or performing voxel-based lesion-symptom mapping ($p < 0.05$, corrected for false discovery rate), revealed a 2-mm³ “coma-specific region” significantly more involved by coma lesions compared to control lesions, located in the left pontine tegmentum, near the medial parabrachial nucleus (figure 1, C–E). Ten of 12 coma

Figure 1 Lesion analysis



(A) Twelve coma lesions exhibited greatest overlap in the upper pontine tegmentum. (B) Twenty-four control lesions exhibited greatest overlap in the pontine base. Subtracting the control lesion voxels from the coma lesion voxels (C) and voxel-based lesion-symptom mapping ($p < 0.05$, corrected) (D) yielded a coma-specific region in the left pontine tegmentum (red). (E) Multiple nuclei implicated in arousal surround the coma-specific region, including the dorsal raphe (yellow dots), locus coeruleus (black dots), and parabrachial nucleus (red dashed line). 4V = fourth ventricle; ml = medial lemniscus; mlf = medial longitudinal fasciculus; scp = superior cerebellar peduncle.

lesions, but only the periphery of 1 of 24 control lesions, involved this region (figure e-2A). The 2 coma lesions that spared this region involved the mid-brain immediately rostral to it (figures e-2, B and C, and e-3A). Some coma-causing lesions involved this left-lateralized region alone, without appearing to extend, at least within limits of MRI resolution, into the right pontine tegmentum or midline midbrain (e.g., cases 8 and 9, figure e-1A).

Network analysis. To identify brain regions in the network of the coma-specific region, we performed an

rs-fcMRI analysis of data from a large cohort of healthy participants.⁷ This analysis revealed 2 nodes functionally connected to our brainstem region: one node was located in the left ventral, anterior insula (AI) (in an agranular subregion also known as frontoinsula cortex¹⁶) extending into a small portion of the claustrum, and the second was located in the pregenual anterior cingulate cortex (pACC) (figures 2 and e-3, B and C; table e-2). These findings were similar with or without regression of the global signal (figure e-4)¹⁷ and were not driven by CSF signal (figure e-5). Voxels within both nodes were functionally connected to all 12 coma lesions (figure 2C), and were significantly more connected to coma lesions than to control lesions ($p < 0.05$; figure 2D). At a lower statistical threshold, the coma-specific region showed connectivity to midline and lateral thalamus, posterior hypothalamus, and basal forebrain (figure e-6). However, unlike connectivity to the AI and pACC, none of these connections were specific to coma lesions over control lesions.

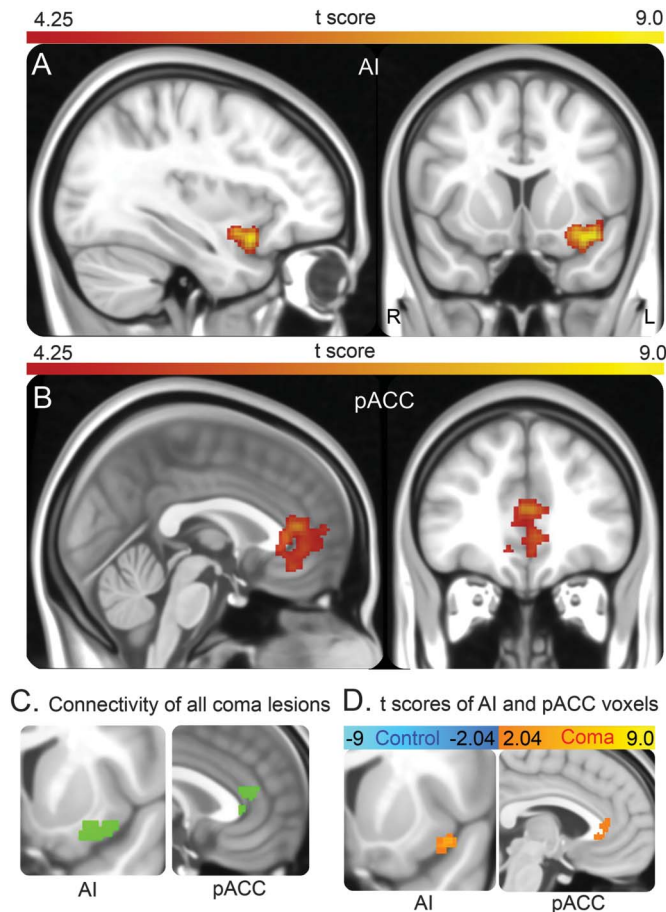
Together, the AI and pACC do not match any cortical network previously defined by rs-fcMRI analysis^{10,11}: the AI node straddles the salience network, limbic network, and default mode network, while the pACC node falls mostly within the default mode network. However, these 2 cortical regions are histologically unique as 2 primary sites of VENs, spindle-shaped neurons found in a select group of mammalian species (see discussion). Microscopic plotting of VENs in a human brain revealed that the AI and pACC nodes identified here correspond more closely to the VEN distribution than to any major resting-state network (figures 3 and e-7).

We conducted 3 additional analyses to further investigate rs-fcMRI between the coma-specific brainstem region, AI, and pACC. First, we used partial correlations to assess the directness of connectivity between each node.¹⁸ Stronger partial correlations were observed between the brainstem node and AI ($r = 0.15$) and between the AI and pACC ($r = 0.26$), than between the brainstem node and pACC ($r = 0.06$). This pattern persisted when using unweighted (i.e., binarized) seeds (figure e-8).

Second, we investigated the brainstem connectivity of the AI and pACC nodes. The AI node exhibited connectivity to the original brainstem node, and less so to a symmetric region of the contralateral pontine tegmentum (figure 4A). In contrast, the pACC node exhibited connectivity to the midline pontine base, not the tegmentum (figure 4B).

Third, we investigated the laterality of our fcMRI findings by flipping the brainstem node to the right and rerunning the connectivity analysis. The left AI and pACC remained the only cortical sites with

Figure 2 Network analysis



The coma-specific brainstem region exhibits functional connectivity to clusters in the anterior insula (AI) (A) and pregenual anterior cingulate cortex (pACC) (B). Voxels within these nodes were functionally connected to all 12 coma lesions (green) (C) and were more functionally connected to coma lesions (orange; $p < 0.05$) than control lesions (blue; $p < 0.05$) (D).

significant connectivity to the right-flipped brainstem node. Compared to the original left-sided brainstem node, these regions were more weakly connected with the right-flipped brainstem node: volumes of significantly connected voxels were smaller (AI 2.0 vs 3.4 cm^3 ; pACC 1.6 vs 5.6 cm^3), and mean t scores were reduced (AI 5.43 vs 5.89; pACC 4.75 vs 4.85).

AI-pACC connectivity in disorders of consciousness. Finally, we used rs-fcMRI to investigate connectivity of our network in patients with disorders of consciousness, including coma, MCS, and VS/UWS.¹⁹ We focused our analysis on cortical AI-pACC connectivity because (1) brainstem connectivity was unreliable in this smaller dataset, and (2) this facilitated comparison to other cortical networks, including the default mode network and motor network. In comatose patients, connectivity was absent (not significantly different from zero) across all 3 networks. In patients with disrupted awareness (MCS or VS/UWS), connectivity was reduced in all networks ($p < 0.001$), but only

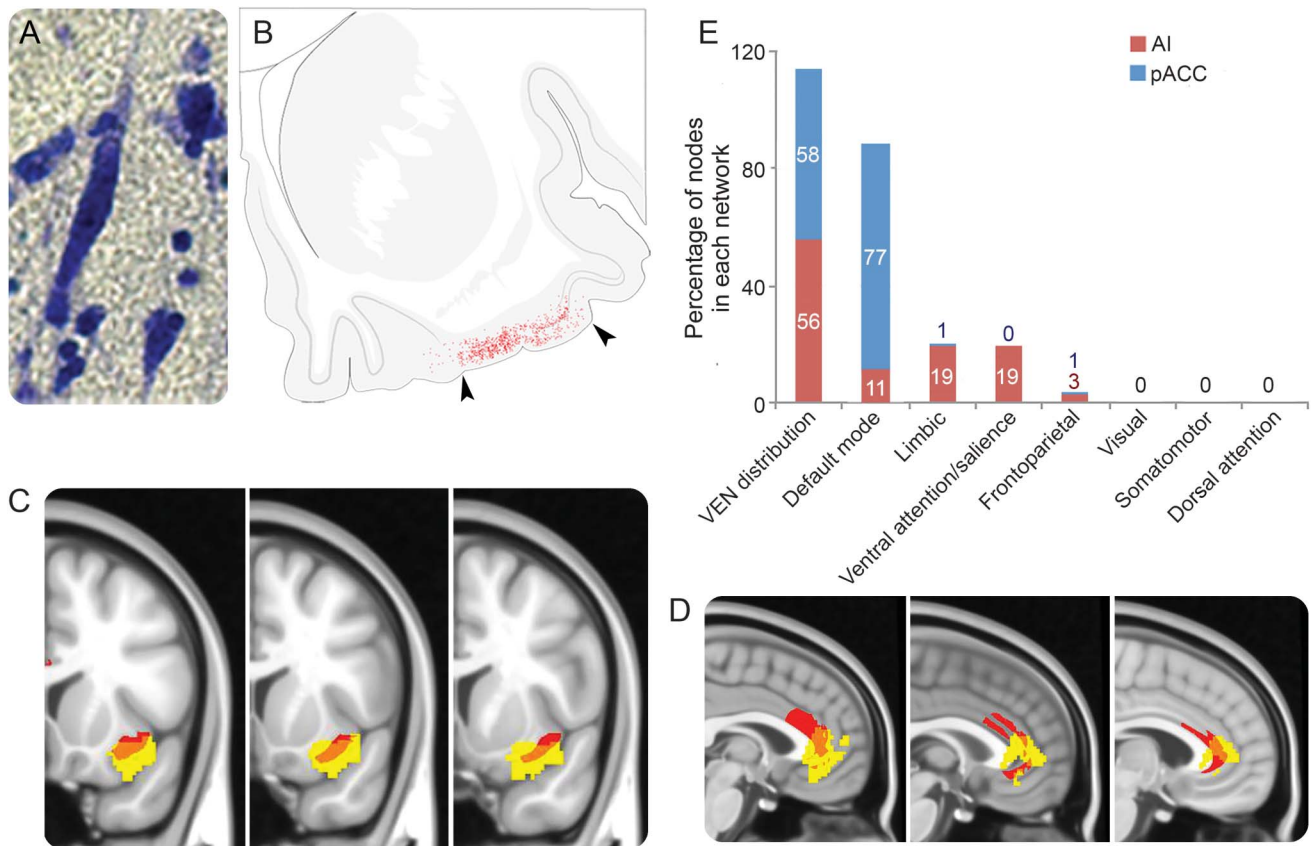
absent between the AI and pACC (figure 5). This reduction in AI-pACC connectivity exceeded that of other networks ($p < 0.05$) including the default mode network, a network previously implicated in disorders of consciousness.²⁰ Splitting MCS and VS/UWS into separate groups, only AI-pACC connectivity was absent in both groups. Motor network connectivity was present in both groups, and default mode network connectivity was present in MCS and absent in VS/UWS (figure e-9).

DISCUSSION In this article, we identify and characterize a human brain network derived from coma-causing brainstem lesions. First, we show that a small region of the left rostral dorsolateral pontine tegmentum is significantly more associated with coma-causing compared to control lesions, implicating it in arousal. Next, we show that this brainstem region is functionally connected to the left AI, and secondarily to the pACC. Finally, we show that patients with disorders of consciousness exhibit a connectivity deficit between the AI and pACC.

Disrupting neurons bilaterally in or near the medial parabrachial nucleus impairs arousal in rodents.^{2,21} Our findings suggest that a similar brainstem region is important for arousal in humans. These findings replicate and extend those of Parvizi and Damasio (2003),³ refining the localization of this region by incorporating more coma-causing lesions and statistical comparisons to control lesions. Of note, in our results, this arousal-promoting brainstem region was relatively left-lateralized. This finding runs counter to conventional wisdom that a lesion must destroy midline or bilateral brainstem tissue to impair consciousness.^{1,3} As such, this finding should be interpreted with caution and requires replication in larger cohorts. However, there are reasons to think this result may be important. First, the left parabrachial region exhibited stronger connectivity to the identified network than the homologous parabrachial region on the right, suggesting that brainstem connectivity in this region may be asymmetric. Second, the left parabrachial region is more active during wake relative to sleep.²² Finally, hemorrhages can occur unilaterally in the right pontine tegmentum without disrupting consciousness.²³

Brainstem arousal neurons project through an ascending activating system (i.e., ARAS), but the targets of this system are unclear.^{2,9} Our results suggest that the left AI, and secondarily the pACC, may be important targets of this system. These functional connectivity results are consistent with known axonal projections between the parabrachial region and AI²⁴ and from the AI to ACC²⁵ in rodents and monkeys. Other regions that receive axonal projections from the

Figure 3 von Economo neuron distribution



von Economo neurons (VENs), identified by their spindle morphology (A), are located in the agranular region (demarcated with black arrowheads) of the anterior insula, represented by red dots (B). The distribution of VENs (red) closely corresponds to the regions of the network nodes (yellow) in the agranular anterior insula (AI) (C) and pregenual anterior cingulate cortex (pACC) (D). The AI and pACC nodes correspond closely to the distribution of VENs, and not to any previously defined resting-state network (E). Rather, the network spans several other resting-state networks.

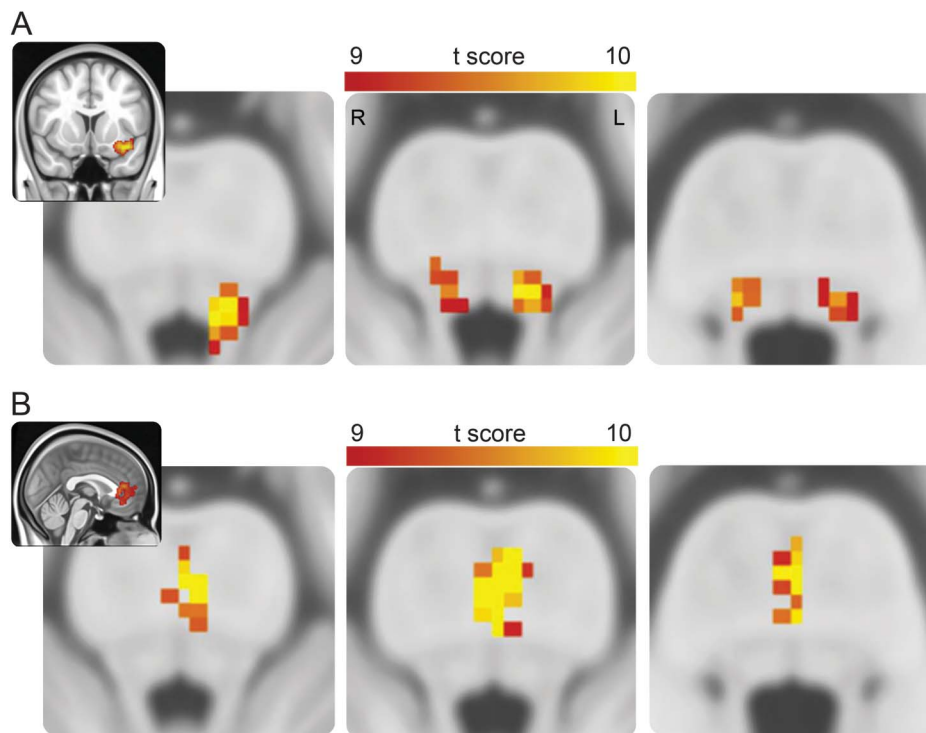
parabrachial region include the thalamus, hypothalamus, basal forebrain, central nucleus of the amygdala, and bed nucleus of the stria terminalis.^{2,4,8,9} Several of these regions exhibited functional connectivity to our coma-specific brainstem region at lower thresholds but failed to show selective connectivity to coma lesions over control lesions. This nonspecific connectivity may reflect limitations of our functional connectivity technique (see below) but may also indicate that some of these structures are not as critical to arousal as once thought: large thalamic ablations, for instance, do not impair wakefulness in experimental animals.²

The 2 regions that did show selective connectivity to coma-causing brainstem lesions, the AI and pACC, were previously implicated in arousal and awareness (i.e., the content of experience). Both regions are more active during wakefulness^{22,26} and autonomic arousal.²⁷ Moreover, the AI and ACC become jointly active during awareness of visual, somatosensory, interoceptive, and other sensory stimuli.^{27,28} Our AI node includes an anterior portion of the claustrum, which has been speculated to have a role in

consciousness.²⁹ Finally, in a case report, electrical disruption of the AI selectively impaired conscious awareness (figure e-10)³⁰; to date, there are no reports of other brain regions producing this effect.

Of note, brainstem connectivity to the AI appears left-lateralized, even when generated from a right-sided brainstem seed. Although unexpected, the implication of left-lateralized cortical regions in sustaining consciousness is supported by prior findings: left hemispheric inhibition with intracarotid amobarbital more frequently disrupts consciousness than right-sided inhibition³¹; decreased connectivity within the left hemisphere, but not the right, predicts diminished levels of consciousness³²; seizures that impair consciousness tend to originate in the left hemisphere³³; loss of consciousness after penetrating trauma is more frequent when the brain injury involves frontotemporal regions of the left hemisphere relative to the right³⁴; and it was the left AI that, when electrically disrupted, eliminated consciousness.³⁰ That said, the right hemisphere may underlie other elements of consciousness, such as attention.³⁵ Thus, the left-lateralization of the network identified here,

Figure 4 Brainstem connectivity of cortical nodes



(A) The anterior insula node exhibits functional connectivity to the coma-specific region, and to a lesser extent, the homologous region of the right pontine tegmentum. (B) The pregenual anterior cingulate node exhibits functional connectivity only to the pontine base. Images are shown from rostral to caudal.

and the lateralization of consciousness more generally, warrants further investigation.

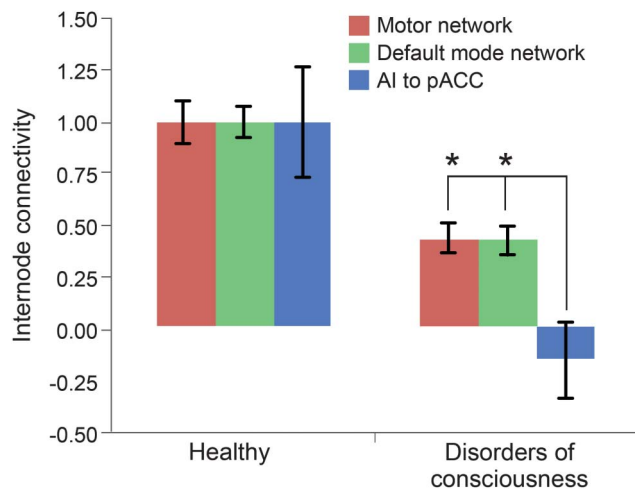
Although we identified our AI and pACC regions based on resting-state functional connectivity with a single site, these regions do not fall within a single

previously defined resting-state network. However, both regions do correspond to the distribution of VENs.³⁶ These spindle-shaped neurons are found in the AI and ACC of particular mammals, such as humans, other great apes, whales, dolphins, and elephants.^{28,36} Based on their large size and dendrites that span all cortical layers, VENs have been proposed to rapidly integrate and transmit information across large brains.³⁶ Species with VENs in the AI and ACC are generally capable of more complex cognition, such as self-recognition in a mirror.²⁸ Moreover, selective degeneration of VENs has been observed in behavioral variant frontotemporal dementia, a condition in which cognition and self-regulation are impaired.³⁷ Although the precise function of these neurons remains unknown, it has been speculated that they have a role in some form of self-awareness.^{28,37}

Given that our AI-pACC network was identified by coma-causing lesions, one might expect it to be disrupted in patients with disorders of consciousness. Here, we show that connectivity between the AI and pACC is disrupted in these patients, and to a greater extent than connectivity within the default mode network, a network previously implicated in disorders of consciousness.²⁰

There are several limitations to the current work. First, the rarity of focal brainstem lesions

Figure 5 Network connectivity in disorders of consciousness



In patients with disorders of consciousness (minimally conscious state or vegetative state/unresponsive wakefulness syndrome), connectivity was more diminished between the anterior insula (AI) and pregenual anterior cingulate (pACC) nodes than within the motor or default mode networks (* $p < 0.05$). Error bars represent SEM.

causing coma limited the number of new lesions we could include, so additional cases were acquired from a retrospective literature review, creating potential for selection and reporting bias. Prospective validation in an independent and larger cohort may further refine the coma-specific brainstem region. Second, rs-fcMRI has limited spatial resolution, a factor particularly relevant in the brainstem; better resolution and larger cohorts may refine functional brainstem anatomy further. Third, rs-fcMRI cannot determine whether functional associations are mediated by mono- or polysynaptic connections, or the directionality of these connections, and the absence of rs-fcMRI connectivity does not imply absence of anatomical connectivity. Fourth, several of our results appeared left-lateralized, but because handedness was difficult to ascertain from some comatose patients and our rs-fcMRI dataset cohort was right-handed, it is unknown whether lateralization of this network

depends on hemispheric dominance. Fifth, in disorders of consciousness, AI-pACC connectivity did not differentiate between MCS and VS/UWS. Because both conditions involve severe impairments in awareness, larger cohorts may be necessary to reveal subtle differences in AI-pACC connectivity between these 2 groups. Sixth, given a correlation between insula-ACC connectivity and heart rate variability,³⁸ we cannot exclude the possibility that connectivity differences between healthy individuals and individuals with disorders of consciousness may be confounded by unanticipated differences in heart rate variability. Finally, while lesions involving the insula and cingulate cortex can disrupt aspects of consciousness in humans and experimental animals,²⁸ some patients with extensive ACC or AI lesions later regain consciousness.³⁹ The role of these regions in supporting consciousness, including the possibility of redundant support between regions, must be clarified through further investigation.

In light of the evidence provided, it is worth speculating whether this brainstem-AI-pACC network could have a role in human consciousness. Consciousness is often defined in terms of 2 components: arousal and awareness.^{1,40} While arousal is thought to be sustained through ascending projections of brainstem structures, awareness is thought to depend more on the cerebral cortex.⁴⁰ Here, we identify a network comprising a brainstem region, which when lesioned disrupts arousal, and VEN-containing cortical regions, which show disrupted connectivity in patients with impaired awareness. This network may therefore serve as a neuroanatomical interface between arousal and awareness, the 2 fundamental components of human consciousness.

Comment: Coma-causing brainstem lesions

Accurate diagnosis and prognosis of patients with severe long-term disorders of consciousness (and remission rates from these conditions) are challenging, especially when the patient's capacity to show signs of consciousness is absent. The rate of misdiagnosis in these patients is as high as 43%,¹ and reliable prognostic markers are rare.² This study identifies—in a healthy cohort and in patients in coma—brainstem sites consistently associated with coma, and network areas functionally connected with this brainstem site.³ The novel finding is a coma-specific region in the left pontine tegmentum near the medial parabrachial nucleus that is associated more with coma-producing than with non-coma-producing brainstem lesions. This area's functional connectivity with the left ventral anterior insula (AI) and the pregenual anterior cingulate cortex (pACC) match well with the distribution of von Economo neurons. There are stronger partial correlations between the pontine node and the AI, and between the AI and the pACC, than between the pontine node and the pACC. After flipping the brain activation to the right side, the left AI and pACC remained connected to the pontine node, indicating the existence of a left-lateralized network involving the pons, AI, and pACC.

This study is important for neurologists because it concerns the neurologic evaluation of patients in coma and remission states, to define treatment aims and care; it provides new insights into the neuroanatomical bases of arousal and consciousness in humans and a better understanding of coma-producing brain network disruptions. This new insight can help the establishment of new diagnostic and prognostic neuroimaging markers to reduce misdiagnosis and misprognosis that are of great value in an era of increasing cost pressure in health care when neurologists must still recommend the best acute treatment and neurorehabilitation for their patients.

1. Schnakers C, Vanhaudenhuyse A, Giacino J, et al. Diagnostic accuracy of the vegetative and minimally conscious state: clinical consensus versus standardized neurobehavioral assessment. *BMC Neurol* 2009;9:35.
2. Gossesies O, Pistoia F, Charland-Verville V, Carolei A, Sacco S, Laureys S. The role of neuroimaging techniques in establishing diagnosis, prognosis and therapy in disorders of consciousness. *Open Neuroimag J* 2016;10:52–68.
3. Fischer DB, Boes AD, Demertzi A, et al. A human brain network derived from coma-causing brainstem lesions. *Neurology* 2016;87:2427–2434.

S.M. Golaszewski, MD, MEng

From the Department of Neurology and Neuroscience Institute, Christian Doppler Clinic, Paracelsus Medical University Salzburg, Austria.

Study funding: No targeted funding reported.

Disclosure: The author reports no disclosures relevant to the manuscript. Go to Neurology.org for full disclosures.

AUTHOR CONTRIBUTIONS

D.B.F., A.D.B., M.D.F., J.C.G., and A.P.-L. contributed to study design. D.B.F., A.D.B., B.L.E., H.L., and J.C.G. collected lesions. D.B.F. and J.C.G. reproduced lesions. D.B.F., A.D.B., and M.D.F. conducted statistical analyses. D.B.F., C.B.S., and J.C.G. analyzed brainstem histology. A.D. and S.L. collected and analyzed data from patients with disorders of consciousness. J.C.G. and H.C.E. plotted von Economo neurons. H.C.E. prepared the binarized von Economo neuron masks. D.B.F. wrote the manuscript. All authors discussed the results and commented on the manuscript.

STUDY FUNDING

This work was supported by the Howard Hughes Medical Institute, the Parkinson's Disease Foundation, the NIH (Shared Instrument Grant S10RR023043, K23NS083741, R01HD069776, R01NS073601, R01NS085477, R21MH099196, R21NS082870, R21NS085491, R21HD07616, R25NS065743, R25NS070682, T32 HL007901, P01HL095491), American Academy of Neurology/American Brain Foundation, Sidney R. Baer, Jr. Foundation, Harvard Catalyst, the Belgian National Funds for Scientific Research, the European Commission, the James McDonnell Foundation, the European Space Agency, Mind Science Foundation, the French Speaking Community Concerted Research Action (ARC-06/11-340), the Public Utility Foundation "Université Européenne du Travail," "Fondazione Europea di Ricerca

DISCLOSURE

The authors report no disclosures relevant to the manuscript. Go to Neurology.org for full disclosures.

Received April 13, 2016. Accepted in final form September 6, 2016.

REFERENCES

1. Posner J, Saper C, Schiff N, Plum F. Plum and Posner's Diagnosis of Stupor and Coma, 4th ed. Oxford, UK: Oxford University Press; 2007.
2. Fuller P, Sherman D, Pedersen NP, Saper CB, Lu J. Re-assessment of the structural basis of the ascending arousal system. *J Comp Neurol* 2011;519:933–956.
3. Parvizi J, Damasio AR. Neuroanatomical correlates of brainstem coma. *Brain* 2003;126:1524–1536.
4. Magoun HW. An ascending reticular activating system in the brain stem. *AMA Arch Neurol Psychiatry* 1952;67:145–154.
5. Rorden C, Karnath HO, Bonilha L. Improving lesion-symptom mapping. *J Cogn Neurosci* 2007;19:1081–1088.
6. Fox MD, Raichle ME. Spontaneous fluctuations in brain activity observed with functional magnetic resonance imaging. *Nat Rev Neurosci* 2007;8:700–711.
7. Boes AD, Prasad S, Liu H, et al. Network localization of neurological symptoms from focal brain lesions. *Brain* 2015;138:3061–3075.
8. Saper C, Loewy A. Efferent connections of the parabrachial nucleus in the rat. *Brain Res* 1980;197:291–317.
9. Saper CB, Scammell TE, Lu J. Hypothalamic regulation of sleep and circadian rhythms. *Nature* 2005;437:1257–1263.
10. Yeo BTT, Krienen FM, Sepulcre J, et al. The organization of the human cerebral cortex estimated by intrinsic functional connectivity. *J Neurophysiol* 2011;106:1125–1165.
11. Seeley WW, Menon V, Schatzberg AF, et al. Dissociable intrinsic connectivity networks for salience processing and executive control. *J Neurosci* 2007;27:2349–2356.
12. Dehaene I, Dom R. A mesencephalic locked-in syndrome. *J Neurol* 1982;227:255–259.
13. Hawkes C. "Locked-in" syndrome: report of seven cases. *Br Med J* 1974;4:379–382.
14. Nyberg-Hansen R, Løken A, Tenstad O. Brainstem lesion with coma for five years following manipulation of the cervical spine. *J Neurol* 1978;218:97–105.
15. Lu J, Liu H, Zhang M, et al. Focal pontine lesions provide evidence that intrinsic functional connectivity reflects polysynaptic anatomical pathways. *J Neurosci* 2011;31:15065–15071.
16. Seeley WW, Merkle FT, Gaus SE, Craig AD, Allman JM, Hof PR. Distinctive neurons of the anterior cingulate and fronto-insular cortex: a historical perspective. *Cereb Cortex* 2012;22:245–250.
17. Wong CW, Olafsson V, Tal O, Liu TT. The amplitude of the resting-state fMRI global signal is related to EEG vigilance measures. *Neuroimage* 2013;83:983–990.
18. Marrelec G, Krainik A, Duffau H, et al. Partial correlation for functional brain interactivity investigation in functional MRI. *Neuroimage* 2006;32:228–237.
19. Demertzi A, Antonopoulos G, Heine L, et al. Intrinsic functional connectivity differentiates minimally conscious from unresponsive patients. *Brain* 2015;138:2619–2631.
20. Vanhaudenhuyse A, Noirhomme Q, Tshibanda LJJ, et al. Default network connectivity reflects the level of consciousness in non-communicative brain-damaged patients. *Brain* 2010;133:161–171.
21. Benarroch EE. Parabrachial nuclear complex: multiple functions and potential clinical implications. *Neurology* 2016;86:676–683.
22. Jakobson AJ, Laird AR, Maller JJ, Conduit RD, Fitzgerald PB. Brain activity in sleep compared to wakefulness: a meta-analysis. *J Behav Brain Sci* 2012;2:249–257.
23. Caplan LR, Goodwin JA. Lateral tegmental brainstem hemorrhages. *Neurology* 1982;32:252–260.
24. Saper CB. Reciprocal parabrachial-cortical connections in the rat. *Brain Res* 1982;242:33–40.
25. Saleem K, Kondo H, Price J. Complementary circuits connecting the orbital and medial prefrontal networks with the temporal, insular, and opercular cortex in the macaque monkey. *J Comp Neurol* 2008;506:659–693.
26. Braun AR, Balkin TJ, Wesenten NJ, et al. Regional cerebral blood flow throughout the sleep-wake cycle: an H2 (15)O PET study. *Brain* 1997;120:1173–1197.
27. Medford N, Critchley HD. Conjoint activity of anterior insular and anterior cingulate cortex: awareness and response. *Brain Struct Funct* 2010;214:535–549.
28. Craig ADB. How do you feel—now? The anterior insula and human awareness. *Nat Rev Neurosci* 2009;10:59–70.
29. Crick FC, Koch C. What is the function of the claustrum? *Philos Trans R Soc Lond B Biol Sci* 2005;360:1271–1279.
30. Koubeissi MZ, Bartolomei F, Beldagy A, Picard F. Electrical stimulation of a small brain area reversibly disrupts consciousness. *Epilepsy Behav* 2014;43:32–35.
31. Glosser G, Cole LC, Deutsch GK, et al. Hemispheric asymmetries in arousal affect outcome of the intracarotid amobarbital test. *Neurology* 1999;52:1583–1590.
32. Rosazza C, Andronache A, Sattin D, et al. Multimodal study of default-mode network integrity in disorders of consciousness. *Ann Neurol* 2016;79:841–853.
33. Englot DJ, Yang L, Hamid H, et al. Impaired consciousness in temporal lobe seizures: role of cortical slow activity. *Brain* 2010;133:3764–3777.
34. Salazar A, Grafman J, Vance S, Weingartner H, Dillon J, Ludlow C. Consciousness and amnesia after penetrating head injury: neurology and anatomy. *Neurology* 1986;36:178–187.
35. Corbetta M, Shulman GL. Spatial neglect and attention networks. *Annu Rev Neurosci* 2011;34:569–599.
36. Allman JM, Tetreault NA, Hakeem AY, et al. The von Economo neurons in fronto-insular and anterior cingulate cortex in great apes and humans. *Brain Struct Funct* 2010;214:495–517.
37. Seeley WW, Carlin DA, Allman JM, et al. Early fronto-temporal dementia targets neurons unique to apes and humans. *Ann Neurol* 2006;60:660–667.
38. Chang C, Metzger CD, Glover GH, Duyn JH, Heinze HJ, Walter M. Association between heart rate variability and fluctuations in resting-state functional connectivity. *Neuroimage* 2013;68:93–104.
39. Philippi CL, Feinstein JS, Khalsa SS, et al. Preserved self-awareness following extensive bilateral brain damage to the insula, anterior cingulate, and medial prefrontal cortices. *PLoS One* 2012;7:e38413.
40. Laureys S, Boly M, Moonen G, Maquet P. Two dimensions of consciousness: arousal and awareness. *Encycl Neurosci* 2009;2:1133–1142.

Neurology[®]

A human brain network derived from coma-causing brainstem lesions

David B. Fischer, Aaron D. Boes, Athena Demertzi, et al.

Neurology 2016;87;2427-2434 Published Online before print November 4, 2016

DOI 10.1212/WNL.0000000000003404

This information is current as of November 4, 2016

Updated Information & Services	including high resolution figures, can be found at: http://www.neurology.org/content/87/23/2427.full.html
Supplementary Material	Supplementary material can be found at: http://www.neurology.org/content/suppl/2016/11/04/WNL.0000000000003404.DC1.html
References	This article cites 39 articles, 16 of which you can access for free at: http://www.neurology.org/content/87/23/2427.full.html##ref-list-1
Citations	This article has been cited by 1 HighWire-hosted articles: http://www.neurology.org/content/87/23/2427.full.html##otherarticles
Subspecialty Collections	This article, along with others on similar topics, appears in the following collection(s): All Cerebrovascular disease/Stroke http://www.neurology.org/cgi/collection/all_cerebrovascular_disease_stroke Coma http://www.neurology.org/cgi/collection/coma fMRI http://www.neurology.org/cgi/collection/fmri Functional neuroimaging http://www.neurology.org/cgi/collection/functional_neuroimaging
Permissions & Licensing	Information about reproducing this article in parts (figures, tables) or in its entirety can be found online at: http://www.neurology.org/misc/about.xhtml#permissions
Reprints	Information about ordering reprints can be found online: http://www.neurology.org/misc/addir.xhtml#reprintsus

Neurology® is the official journal of the American Academy of Neurology. Published continuously since 1951, it is now a weekly with 48 issues per year. Copyright © 2016 American Academy of Neurology. All rights reserved. Print ISSN: 0028-3878. Online ISSN: 1526-632X.

